

Hepatico-jejuno-duodenal access loop – a modified biliary reconstruction technique for facilitated endoscopic access to biliary tree following surgery for hepatolithiasis

Abdul Rehman Abdul Jameel, Anbalagan Pitchaimuthu, Prabhakaran Raju, Rajendran Shanmugasundaram, Naganath Babu Obla, Kannan Devy Gounder

ABSTRACT

Aims: Management of hepatolithiasis is complicated by residual and recurrent disease, and endoscopic access to biliary tree in such patients enables therapeutic interventions thereby avoiding the morbidity associated with relaparotomy. In this study we assess a modified biliary reconstruction in the form of hepatico-jejuno-duodenal access loop (HJDA) with regard to the feasibility of endoscopic access to intrahepatic ducts with follow-up. **Methods:** From August 2011 till December 2016, all patients treated for hepatolithiasis with bilateral disease, non-dilated extrahepatic biliary system or extensive intrahepatic strictures underwent HJDA. After completion of hepaticojejunostomy (HJ), the free end of the Roux loop was anastomosed to the first part of duodenum in a side to side fashion. In the fourth week postoperatively, endoscopy with conventional forward viewing endoscope was performed to explore the possibility of accessing the biliary system. **Results:** Endoscopic access to the intrahepatic bile ducts through the

HJDA was possible in all the patients and mean time taken to access the HJ was 3.5 minutes (2-7 minutes). There were no complications pertinent to construction of the HJDA. One patient had bile leak from HJ, which settled with conservative management and surgical site infection was seen in four. We did not have any mortality in our series. During the follow up, three of our patients (30%) subsequently presented with cholangitis at a mean period of 22 months and were successfully managed with endoscopic procedures alone. One patient required balloon dilatation of the HJ stricture, while the other two were managed by endoscopic removal of calculi. Overall, five endoscopic procedures were required in three patients with recurrent cholangitis in the follow up period with rate of 1.67 procedures per patient. **Conclusion:** HJDA is a modified biliary reconstruction technique which facilitates endoscopic access to the biliary system for removal of recurrent/residual intrahepatic stones. It is therefore recommended in patients with complicated hepatolithiasis like bilateral disease, recurrence, multiple intrahepatic strictures and for those in whom future endoscopic access to biliary tree is deemed necessary.

Keywords: Access loop, Hepatolithiasis, Hepatojejunoduodenal

Abdul Rehman Abdul Jameel¹, Anbalagan Pitchaimuthu¹, Prabhakaran Raju², Rajendran Shanmugasundaram², Naganath Babu Obla², Kannan Devy Gounder¹

Affiliations: ¹Department of Surgical Gastroenterology - Saveetha University – Saveetha Medical College and Hospital, Thandalam, Chennai, India; ²Institute of Surgical Gastroenterology, Madras Medical College, Chennai, India.

Corresponding Author: Dr. Anbalagan Pitchaimuthu MCh, Department of Surgical Gastroenterology, Saveetha Medical College and Hospital, Saveetha University, Thandalam, Chennai-602 105, India; Email: anbalagansge@gmail.com

Received: 17 April 2018
Accepted: 27 September 2018
Published: 05 December 2018

How to cite this article

Jameel ARA, Pitchaimuthu A, Raju P, Shanmugasundaram R, Obla NB, Gounder KD. Hepatico-jejuno-duodenal access loop – a modified biliary reconstruction technique for facilitated endoscopic access to biliary tree following surgery for hepatolithiasis. Int J Hepatobiliary Pancreat Dis 2018;8:100080Z04AJ2018.

doi: 10.5348/100080Z04AJ2018OA

INTRODUCTION

Hepatolithiasis is defined as the presence of calculi or concretions proximal to the confluence of the right and left hepatic ducts, irrespective of the coexistence of gallstones in the common bile duct and/or gallbladder. This disease is endemic in the Asia-Pacific region, where its prevalence can be as high as 30–50% [1]. Although it is rare in the West, with a prevalence of 0.6–1.3% [2], it is not very uncommon in India [3]. Natural history of intrahepatic duct calculi is associated with repeated cholangitis can lead to progressive multiple biliary strictures, liver abscess, liver cirrhosis, atrophy of involved segments, secondary biliary cirrhosis and even cholangiocarcinoma [4].

Therapeutic modalities aim to prevent liver damage by early clearance of calculi and avoiding bile stasis. The options include surgical exploration of the biliary tree, hepatic resection and percutaneous transhepatic cholangioscopic lithotomy (PTCSL) [5]. Complete clearance of intrahepatic strictures and calculi is technically not feasible in all cases with stone clearance rate being 83.3% for patients undergoing hepatic resection, and 63.9% in those managed by PTCSL in a study [5]. Despite the best possible treatment, management of hepatolithiasis is complicated by a high rate of treatment failures characterized by residual stones, recurrence of stones proximal to intrahepatic biliary strictures and recurrent cholangitis proceeding to biliary cirrhosis, portal hypertension and liver failure. Incidence of recurrent stones and cholangitis are quite common, with frequency of 30–35% after surgery [6] and 31–40% after PTCSL [7] respectively.

Access to the biliary tree is an essential component in the management of hepatolithiasis, to manage the residual and recurrent stones, as well as the ductal strictures by endoscopic or percutaneous techniques. These include stone retrieval through the T-tube tract [8], or through an access loop placed as a stoma [9] or concealed in the parieties [10] which is accessed by puncture under fluoroscopic guidance. Alternatively, Roux-en-Y limb of the hepaticojejunostomy could be anastomosed to the stomach [11–13] or duodenum [14] to allow endoscopic access to the bile ducts. We describe our experience and long term results of hepatico-jejuno-duodenal access (HJDA) loop in patients undergoing surgery for intrahepatic calculi.

MATERIALS AND METHODS

26 patients underwent surgical management for hepatolithiasis at the Institute of Surgical Gastroenterology, Madras Medical College, Chennai and in 10 patients HJDA was constructed between Aug 2011 and Dec 2016. All the patients were resident of Tamilnadu, India. Patient demographic profile, clinical presentation along with laboratory values including complete hemogram, liver function tests, charlson comorbidity index, renal function tests, cancer antigen 19-9 (CA 19-9) and carcinoembryonic antigen (CEA) were prospectively maintained in our database. Patients were thoroughly evaluated with ultrasound abdomen, portal doppler, computed tomography and magnetic resonance cholangio-pancreatography (MRCP) as indicated. Choice of the surgical procedure was individually tailored based on the presence of unilateral or bilateral hepatic lobar involvement, lobar atrophy, diameter of common bile duct (CBD), presence of intrahepatic strictures or cholangiolytic abscesses and suspicion of harbouring cholangiocarcinoma.

Cholecystectomy (if not performed earlier), was followed by CBD exploration via choledochotomy close to hilum to facilitate intrahepatic stone clearance by saline flush and employing Desjardin's forceps. Intraoperative choledochoscopy was performed in all cases to ensure complete clearance of the stone load. Liver resection on involved segments was performed, in cases of unilateral involvement with lobar atrophy, chronic abscess with cholangitis, multiple intrahepatic ductal strictures and suspicion of cholangiocarcinoma.

Our Institute's policy is to ensure future endoscopic access to bile ducts in all patients; this is accomplished by either choledochoduodenostomy (CDD) or by HJDA. In those with dilated CBD (>1.5cm) with no intrahepatic ductal strictures, we perform CDD whereas HJDA is constructed for patients who had bilateral disease, non-dilated extrahepatic biliary system or extensive intrahepatic strictures. The clinical details of patients who underwent HJDA are given in table 1.

Technique of HJDA construction

The hilar plate is lowered and hepatic ducts are defined. We prefer a 3cm long choledochotomy on the hilum extending to left or right duct. Following the successful clearance of stones from the biliary tree, a 55-cm-long Roux-en-Y loop is prepared and HJ constructed using interrupted 000 PDS (polydioxanone) sutures leaving a distal 15cm of the roux loop for subsequent anastomosis with the duodenum. After completion of HJ, the end of Roux loop is anastomosed with the first part of duodenum, in a side to side fashion using a single layer of interrupted 00 vicryl. Thus, the jejuno-duodenal anastomosis is constructed approximately 7–10 cm

Table 1: Details of patients who underwent HJDA

No	age	Sex/ BMI	Previous surgery/ Charlson comorbidity index (CCI)	Disease characte ristics	Procedure	Post-op complic ations	Endos copic access to HJ*	Follo w up (mon ths)	Recurr ent Cholan gitis	No of endotherapy sessions
1	48	F 21	None/CCI - 1	Seg 2,3 atrophy Bilateral disease	Left lateral segmentec tomy with HJDA	None	Successful	62	Yes	1
2	36	M 22	Right hepatecto my with CDD/ CCI - 1	Left hepatic ductal strictures with multiple recurrent calculi	HJDA	Wound infection	Successful	44	Yes	1
3	45	M/26	None/ CCI - 2	Bilateral Disease	HJDA	None	Successful	38	No	0
4	42	F/25	Open cholecyst ectomy/ CCI - 1	Bilateral Disease	HJDA	None	Successful	35	No	0
5	54	F/22	None/CCI - 3	Bilateral Disease	HJDA	None	Successful	32	No	0
6	38	F/26	None/CCI – 2	Left hepatic duct strictures with cholangio lytic abscess Bilobar disease	Left hepatecto my with HJDA	Bile leak Wound infection	Successful	25	Yes	3
7	52	M/22	Open CBD exploratio n and CDD/ CCI – 2	Bilateral disease	HJDA	None	Successful	22	No	0
8	36	F/21	Open cholecyst ectomy/ CCI - !	Seg 2,3 atrophy Bilateral disease	Left lateral segmentec tomy with HJDA	None	Successful	18	No	0
9	28	F/24	Choledoc hal cyst Type IVa Cyst Excision/ CCI - 1 and HJ	Bilateral disease with HJ stricture	Repeat HJ with duodenal access loop	Wound infection	Successful	16	No	0
10	48	F/23	HJ for hepatolith iasis/ CCI - 2	Bilateral disease with HJ stricture	Repeat HJ with duodenal access loop	Wound infection	Successful	13	No	0

F, female; HJDA, hepatico-jejuno-duodenal access loop; M, male; HJ, hepaticojejunostomy, BMI – Body Mass Index, CCI – Charlson comorbidity index

* done at four weeks after surgery

below the HJ (Figures 1, 2). We routinely advance the nasogastric tube into the second part of duodenum, and is removed on second post-operative day. A soft abdominal drain of 24Fr is placed in the morrison's pouch.

All patients underwent check endoscopy using conventional forward viewing endoscopes after 4 weeks to document the ability to access the bile ducts. If any calculi were visualised, they were removed using endoscopic adjuncts under fluoroscopic guidance. Patients developing complications such as bile leak, wound infection etc were recorded and treated accordingly. Patients were kept on regular follow up and endoscopy was performed when they had cholangitis or raised liver function tests.

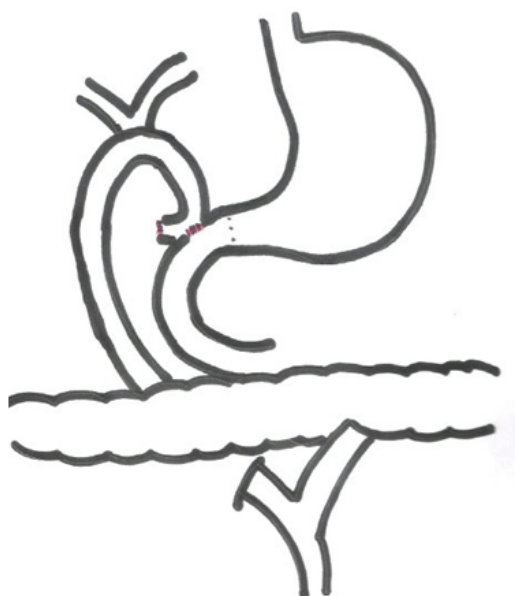


Figure 1: Showing the scheme of construction of Hepatico-jejunostomy.

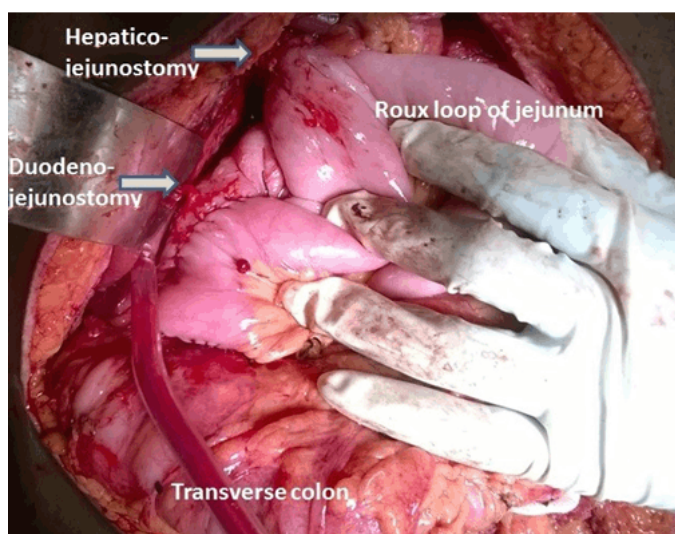


Figure 2: intraoperative photo showing HJDA reconstruction.

RESULTS

In the period of the study, 10 patients were managed with HJDA by the authors. Seven patients were females and three were males. The age of the patients ranged from 28 to 54 years with a mean age of 42.7 years. The mean operative time was 164 minutes (range 122–286 minutes). We did not encounter any mortality in our series. One patient had bile leak from HJ which settled with conservative management and surgical site infection was seen in four. There were no complications attributable to construction of the HJDA. Endoscopic access to the intrahepatic bile ducts through the HJDA was possible in all the patients, which was performed four weeks following the surgery. The mean time taken to access the hepaticojejunostomy through the duodenal access loop during endoscopy was 3.5 minutes in these patients (range 2 to 7 minutes).

The follow up period of our patients ranged from 13 to 62 months with a mean follow up of 30.5 months. Three of our patients (30%) subsequently presented with cholangitis at a mean period of 22 months following surgery. The patient who had bile leak in the post-operative period developed HJ stricture and underwent endoscopic dilatation using through the scope (TTS) balloon and subsequently required two more endotherapy sessions to clear the recurrent stones. The other two patients, who presented with cholangitis, were managed with endoscopic removal of calculi alone with dormia basket (Figure 3). Overall, five endoscopic procedures were required in three patients with recurrent cholangitis (30%) in the follow up period with rate of 1.67 procedures per patient. There were no patients lost to follow up in

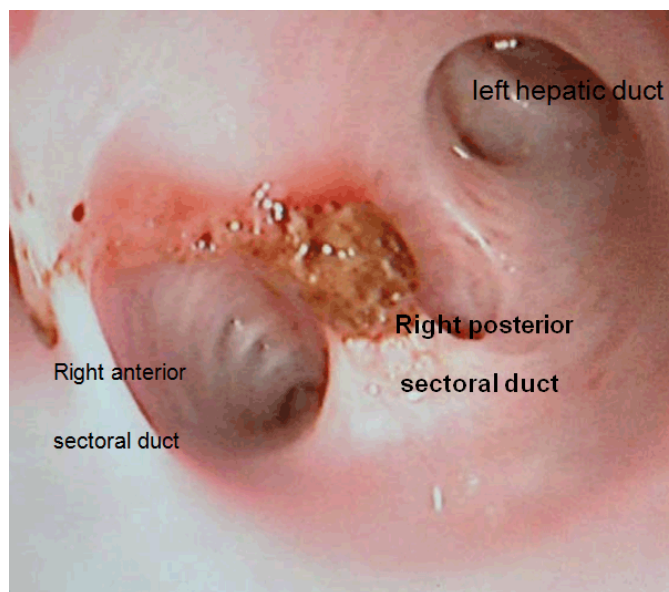


Figure 3: Forward viewing endoscopy through the HJDA shows the presence of the recurrent calculi in right anterior sectoral duct, which was subsequently removed by dormia basket.

our series and all are under vigilant follow up. We did not encounter any difficulty in endoscopic access in our patients in the follow up period with regard to development of redundancy of the jejunal loop over time.

DISCUSSION

Successful management of hepatolithiasis depends on the ability to ensure clearance of the stones and avoiding bile stasis. Despite all efforts, none of the available therapeutic options can ensure complete clearance and post treatment follow-up is complicated by retained and recurrent stones. The incidence for such complications tends to increase as the duration of follow-up prolongs. Reoperation for disease recurrence is fraught with difficulty in accessing the bile duct due to dense peri-hilar adhesions. Our case series demonstrated that HJDA was advantageous in the management of hepatolithiasis as it provided a pathway for extraction of residual stones and ensured that it can be accomplished non-operatively.

An alternative approach to access the biliary tree for intervention in the follow up period is by PTCSL technique, which is being increasingly utilised by the interventional radiologists. Stone clearance rates of 80 per cent have been achieved with repeated procedures [15]. Problems with this approach includes the necessity for serial dilatation for up to three weeks for the maturation of the working tract and many patients develop severe pain and bleeding resulting in treatment failures [16]. The access through a percutaneous placed transhepatic catheter is only temporary and is lost once the catheter is removed. Extraction of calculi through a T tube tract approach, if placed intraoperatively has also been suggested. It has lost favour due to pain at cutaneous entry site, loss of tract during dilatation and loss of stones during extraction especially if the stones are larger than the tract diameter [17].

The initial description of the access loop involved Roux-en-Y hepaticocutaneous jejunostomy. Although it permitted endoscopic access for removal of residual stones, it necessitated the fashioning of a stoma which had unpleasant side-effects of bile discharge and skin excoriation. Poor tolerance by patients necessitated early closure of stoma in many patients. Stoma closure was also associated with significant complications like wound infection, fistula formation and incisional hernia [18]. Also, many patients required reopening of the stoma for removal of recurrent stones after two years of follow-up [18]. Modifications of the cutaneous access loop include placing an intussuscepting flap valve by plicating seromuscular sutures [19] and

subfascial placement [10] of the access loop for subsequent puncture through fluoroscopic guidance. These have not found much acceptance because of being not effective and may also result in parajejunal herniation [20].

Anastomosis of the end of the Roux loop to stomach - Gastric access loop was first described by Sitaram et al. [11] in ten patients. They successfully entered the enterogastrostomy in only five patients. Selvakumar et al. [12] reported eleven patients with gastric access loop with 73% success rate of endoscopic access of the HJ stoma and three patients developed jejunogastrostomy stricture. The reason for jejunogastrostomy stricture could be the exposure of the jejunum to acid environment causing peptic stricture. Both the studies reported no evidence of bile gastritis and attributed this to the inability of the stomach contents to enter the access loop as long as the normal pyloroduodenal channel is intact. Stiegmann et al [14] first described duodenal access loop in seven patients with anastomosis of end of Roux loop to the first part of duodenum, either end to side or in side to side fashion. In that study [14] only three patients had endoscopic inspection of the biliary enteric anastomosis from 3 to 24 months postoperatively.

Ramesh et al [21] described their experience with interposition hepaticojejunojejunoduodenostomy in two patients, which involves isolating a segment of proximal jejunum with intact blood supply which is then brought through the transverse mesocolon into the supracolic compartment and is interposed between duodenum and hilar duct. They encountered problems in endoscopic access due to redundancy of the jejunal segment, following which jejunoduodenal access loop was constructed in nine patients in a side to side fashion following the natural lie of Roux loop over the duodenum. Endoscopic access to biliary tree was feasible in all their patients with jejunoduodenal access.

Our experience adds to the available data in literature, in proving that HJDA is a valuable procedure for facilitated access to the biliary tree in patients treated for hepatolithiasis. It can be accomplished with ease and no added procedure related complications. Endoscopic access with conventional forward viewing endoscopes is easily possible in all cases, and serves as a therapeutic modality in cases of recurrence thus avoiding the morbidity associated with re-operation. Although the theoretical risk of ascending cholangitis exists, as the distance between the biliary system and bowel is around 10cm but this has been clinically encountered only in three of our patients. The possible explanation could be due to the peristalsis of the jejunal loop and the flow of bile directed towards the duodenum in preventing the entry of enteric contents into the biliary system.

CONCLUSION

Successful management of hepatolithiasis depends on the judicious choice of available treatment modalities, and it is justifiable to conclude that HJDA is one of the valuable procedures in the overall management of these patients. We recommend that HJDA be done in patients with bilateral disease, incomplete stone clearance, recurrent hepatolithiasis, complicated intrahepatic strictures and for those in whom future access to biliary tree is deemed necessary. In summary, HJDA is a valuable technique in surgical management of hepatolithiasis and can be extended to other indications warranting future endoscopic access to intrahepatic ducts.

REFERENCES

1. Catena M, Aldrighetti L, Finazzi R, Arzu G, Arru M, Pulitanò C et al. (2006). Treatment of non-endemic hepatolithiasis in a Western country. The role of hepatic resection. *Ann R Coll Surg Engl* 88:383-389.
2. Kayhan B, Akdogan M, Parlak E, Ozarslan E, Sahin B. (2007) Hepatolithiasis: a Turkey experience. *Turk J Gastroenterol* 18:28-32.
3. Prakash K, Ramesh H, Jacob G, Venugopal A, Lekha V, Varma D, Ramesh GN, Augustine P. Multidisciplinary approach in the long-term management of intrahepatic stones: Indian experience. *Indian J Gastroenterol*. 2004 Nov-Dec; 23(6):209-13.
4. Kusano T, Isa T, Ohtsubo M, Yasaka T, Furukawa M. Natural progression of untreated hepatolithiasis that shows no clinical signs at its initial presentation. *J Clin Gastroenterol* 2001;33:114-7.
5. Cheon Y, Cho Y, Moon J, Lee J, Shim C. Evaluation of long-term results and recurrent factors after operative and nonoperative treatment for hepatolithiasis. *Surgery*. 2009;146(5):843-853.
6. Chijiwa K, Yamashita H, Yoshida J, Kuroki S, Tanaka M. Current management and long-term prognosis of hepatolithiasis. *Arch Surg* 1995;130:194-7.
7. Otani K, Shimizu S, Chijiwa K, Ogawa T, Morisaki T, Sugitani A, et al. Comparison of treatments for hepatolithiasis: hepatic resection versus cholangioscopic lithotomy. *J Am Coll Surg* 1999;189:177-82.
8. Gott PE, Tieva MH, Barcia PJ, Laberge JM. Biliary access procedure in the management of oriental cholangiohepatitis. *Am. Surg.* 1996; 62: 930-4.
9. Kassem M, Sorour M, Ghazal A, El-Haddad H, El-Riwini M, El-Bahrawy H. Management of intrahepatic stones: The role of subcutaneous hepaticojejunal access loop. A prospective cohort study. *International Journal of Surgery*. 2014;12(9):886-892.
10. Beckingham IJ, Krige JE, Beningfield SJ, Borman PC, Terblanche J. Subparietal hepaticojejunal access loop for the long-term management of intrahepatic stones. *Br. J. Surg.* 1998;85: 1360-3.
11. Sitaram V, Perakath B, Chacko A, Ramakrishna BS, Kurian G, Khanduri P. Gastric access loop in hepaticojejunostomy. *Br. J.Surg.*1998;85: 110.

12. Eswaran Selvakumar, Shanmugasundaram Rajendran, Tirupporur G. Balachandar, Devy Gounder Kannan, Satyanesan Jeswanth, Palaniappan Ravichandran and Rajagopal Surendran. Long-term outcome of gastric access loop in hepaticojejunostomy. *Hepatobiliary Pancreat Dis Int.* 2008 Apr;7(2):152-5
13. Hamad MEL-Amin H. Bilio-entero-gastrostomy: prospective assessment of a modified biliary reconstruction with facilitated future endoscopic access. *BMC 297 Surgery*. 2012;12(1).
14. Stiegmann GV, Mansour MA, Goff JS, Pearlman NW. Rouxen-Y jejunoduodenostomy for endoscopic access to hepaticojejunostomy. *Surg. 300 Gynecol. Obstet.* 1991;173: 153-4.
15. Jan Y, Chen M. Percutaneous trans-hepatic cholangioscopic lithotomy for hepatolithiasis: long-term results. *Gastrointestinal Endoscopy*. 1995;42(1):1-5.
16. Jeng K, Chiang H, Shih S. Limitations of percutaneous transhepatic cholangioscopy in the removal of complicated biliary calculi. *World Journal of 305 Surgery*. 1989;13(5):603-610.
17. Cheung M. Postoperative choledochoscopic removal of intrahepatic stones via a T tube tract. *British Journal of Surgery*. 1997;84(9):1224-1228.
18. Fan S, Mod F, Zheng S, Lai E, Lo C, Wong J. Appraisal of hepaticocutaneous jejunostomy in the management of hepatolithiasis. *The American Journal of Surgery*. 1993;165(3):332-335.
19. Barker EWinkler M. Permanent-access hepaticojejunostomy. *British Journal of Surgery*. 1984;71(3):188-191.
20. Al-Ghnamien R Benjamin I. Long-term outcome of hepaticojejunostomy with routine access loop formation following iatrogenic bile duct injury. *British Journal of Surgery*. 2002;89(9):1118-1124.
21. Ramesh H, Prakash K, Kuruvilla K, Philip M, Jacob G, Venugopal B et al. Biliary access loops for intrahepatic stones: results of jejunoduodenal anastomosis. *ANZ Journal of Surgery*. 2003;73(5):306-312.

Author Contributions

Abdul Rehman Abdul Jameel – Substantial contributions to conception and design, Acquisition of data, Analysis and interpretation of data, Drafting the article, Revising it critically for important intellectual content, Final approval of the version to be published

Anbalagan Pitchaimuthu – Substantial contributions to conception and design, Acquisition of data, Analysis and interpretation of data, Drafting the article, Revising it critically for important intellectual content, Final approval of the version to be published

Prabhakaran Raju – Substantial contributions to conception and design, Acquisition of data, Analysis and interpretation of data, Drafting the article, Revising it critically for important intellectual content, Final approval of the version to be published

Rajendran Shanmugasundaram – Substantial contributions to conception and design, Acquisition of data, Analysis and interpretation of data, Drafting the

article, Revising it critically for important intellectual content, Final approval of the version to be published
Naganath Babu Obla – Substantial contributions to conception and design, Acquisition of data, Analysis and interpretation of data, Drafting the article, Revising it critically for important intellectual content, Final approval of the version to be published

Kannan Devy Gounder – Substantial contributions to conception and design, Acquisition of data, Analysis and interpretation of data, Drafting the article, Revising it critically for important intellectual content, Final approval of the version to be published

Guarantor of Submission

The corresponding author is the guarantor of submission.

Source of Support

None.

Consent Statement

Written informed consent was obtained from the patient for publication of this original article.

Conflict of Interest

Authors declare no conflict of interest.

Data Availability

All relevant data are within the paper and its Supporting Information files.

Copyright

© 2018 Abdul Rehman Abdul Jameel et al. This article is distributed under the terms of Creative Commons Attribution License which permits unrestricted use, distribution and reproduction in any medium provided the original author(s) and original publisher are properly credited. Please see the copyright policy on the journal website for more information.