

# Bleeding and malignant pancreatic neuroendocrine neoplasms: A Malaysian case series

Muthu Viknesh, Faqihuddin Bin Hisham, Padmaan Sankaran, Soon Kong Choon, Nik Azim Bin Nik Abdullah

## ABSTRACT

**Introduction:** Pancreatic neuroendocrine neoplasm (PNEN) is a rare malignancy arising from the endocrine tissue of the pancreas. These tumors are classified based on functional (hormonal) status and malignant potential. Symptoms and signs are related to the hormonal function, tumor size, and metastatic effect. The majority are sporadic, non-functioning while insulinoma remains the most prevalent functional variety of these tumors. **Case Series:** We present two cases of PNEN with different presentations and treatments; one with a resectable disease who presented as a rare case of bleeding PNEN, and the other who was unresectable due to extensive metastatic PNEN. **Conclusion:** Pancreatic neuroendocrine neoplasm is a heterogeneous group of disorder with a multitude of clinical presentation. Each patient must be investigated and managed appropriately according to the treatment of

choice. In keeping with the purpose of this article, we suggest a bleeding PNEN, a rare occurrence, is best managed with surgery, while unresectable metastatic PNEN would benefit from appropriate medical therapy.

**Keywords:** Metastasis, Pancreas, Pancreatic neuroendocrine neoplasm, Surgery

### How to cite this article

Viknesh M, Hisham FB, Sankaran P, Choon SK, Abdullah NABN. Bleeding and malignant pancreatic neuroendocrine neoplasms: A Malaysian case series. Int J Hepatobiliary Pancreat Dis 2019;9:100084Z04MV2019.

Article ID: 100084Z04MV2019

\*\*\*\*\*

doi: 10.5348/100084Z04MV2019CS

Muthu Viknesh<sup>1</sup>, Faqihuddin Bin Hisham<sup>1</sup>, Padmaan Sankaran<sup>2</sup>, Soon Kong Choon<sup>3</sup>, Nik Azim Bin Nik Abdullah<sup>4</sup>

**Affiliations:** <sup>1</sup>Medical Officer, Hepatobiliary Surgery, Sarawak General Hospital, Kuching, Sarawak, Malaysia; <sup>2</sup>Hepatobiliary Surgeon, Hepatobiliary Surgery, Sarawak General Hospital, Kuching, Sarawak, Malaysia; <sup>3</sup>Consultant Hepatobiliary Surgeon, Hepatobiliary Surgery, Sarawak General Hospital, Kuching, Sarawak, Malaysia; <sup>4</sup>Senior Consultant Hepatobiliary Surgeon, Hepatobiliary Surgery, Sarawak General Hospital, Kuching, Sarawak, Malaysia.

**Corresponding Author:** Muthu Viknesh, V304, MJC Court-yard Sanctuary, Batu Kawah New Township, Jalan Batu Kawa 93250, Kuching, Sarawak, Malaysia; Email: mtv-vicky@gmail.com

Received: 04 June 2019  
Accepted: 29 July 2019  
Published: 20 August 2019

## INTRODUCTION

The term neuroendocrine denotes to the properties of “neuro”—based on the identification of dense core granules which store monoamines and “endocrine”—referring to the synthesis and secretion of these monoamines [1]. The most common primary site is the gastrointestinal tract (gastroenteropancreatic NEN: GEP-NEN) (62–67%) and the lungs (22–27%) [2]. We further divide GEP-NEN into neuroendocrine neoplasm of the luminal gastrointestinal tract and pancreatic neuroendocrine neoplasm (PNEN). We report two cases of PNEN with different rare presentations and stage of the disease. Based on our developing experience, we put forward our approach to diagnosing and managing these tumors.

**CASE SERIES****Case 1**

Mr. M, a 30-year-old gentleman with 10 pack-years of smoking, presented with a three-day history of obstructive jaundice and abdominal pain and an acute episode of melena. Besides jaundice, the rest of the physical examination was unremarkable. He was anemic, and liver function test showed an obstructive picture. An esophagogastroduodenoscopy (OGDS) by us revealed a bleeding ampullary tumor which we temporarily arrested with argon plasma coagulation (APC). Ultrasonography (USG) and computed tomography (CT) pancreatic protocol showed a bulky pancreas with a duodenal tumor and dilated biliary and pancreatic duct. The pancreas and the duodenal mass showed arterial enhancement and portal venous washout with no evidence of intra-abdominal metastases. The tumor did not encase the coeliac, superior mesenteric artery, superior mesenteric vein, and portal vein. We did an angiogram; however, no specific point of bleeding was identified to proceed for angioembolization. As his symptoms did not improve, and we could not proceed with any further investigation, we decided to perform a total pancreatectomy and splenectomy after discussing with our local NEN multidisciplinary team. Intraoperatively the entire pancreas was enlarged, hard, and nodular (Figure 1). His recovery was uneventful and was discharged home a week after surgery with subcutaneous insulin. Histopathological examination of the resected specimen revealed a Grade 1, well-differentiated NEN involving the whole length of the pancreas. Three out of 30 lymph nodes harvested were positive for NEN. The entire specimen showed strong positivity for synaptophysin and chromogranin A, and the Ki67 index was 3%. A postoperative serum chromogranin A (CgA) taken four weeks after surgery was 160.6 ng/ml. We organized a <sup>68</sup>Ga-DOTATATE positron emission tomography (PET) scan for completion of staging.

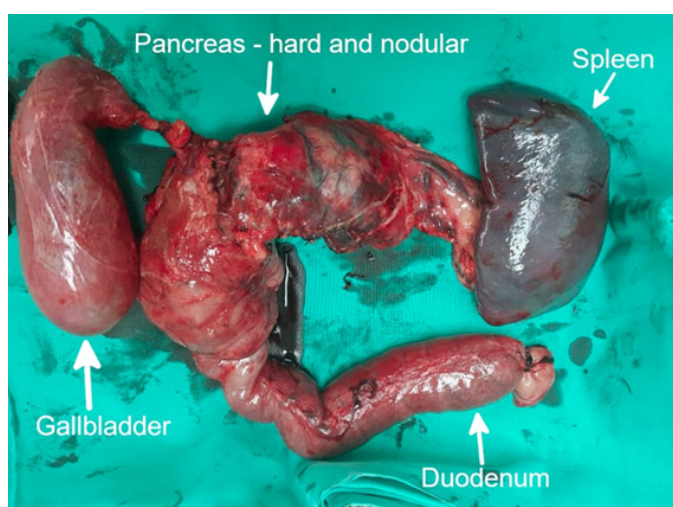


Figure 1: Intraoperative total pancreatectomy specimen.

**Case 2**

Madam S, a 48-year-old lady, with no known previous medical illness, presented with a history of progressive abdominal distension and lethargy for six months. Upon examination, we found a palpable mass encompassing the epigastric, the left hypochondrium and the left lumbar region. Computed tomography of the thorax, abdomen, and pelvis revealed a large mass arising from the entire pancreas, invading the splenic hilum and left pararenal space and displacing the stomach anteriorly with multiple liver and peritoneal metastases and ascites (Figures 2 and 3). A USG-guided biopsy of the mass showed a Grade 2, well-differentiated neuroendocrine

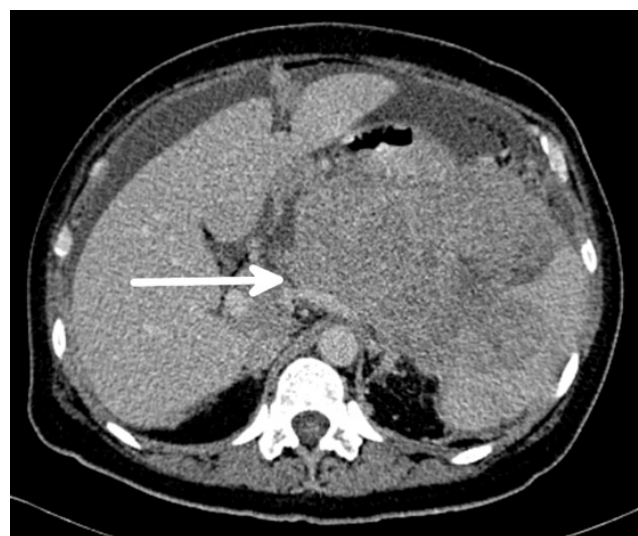

Figure 2: Axial view of contrast-enhanced computed tomography of pancreatic protocol; the white arrow represents the location of the tumor on the scan.

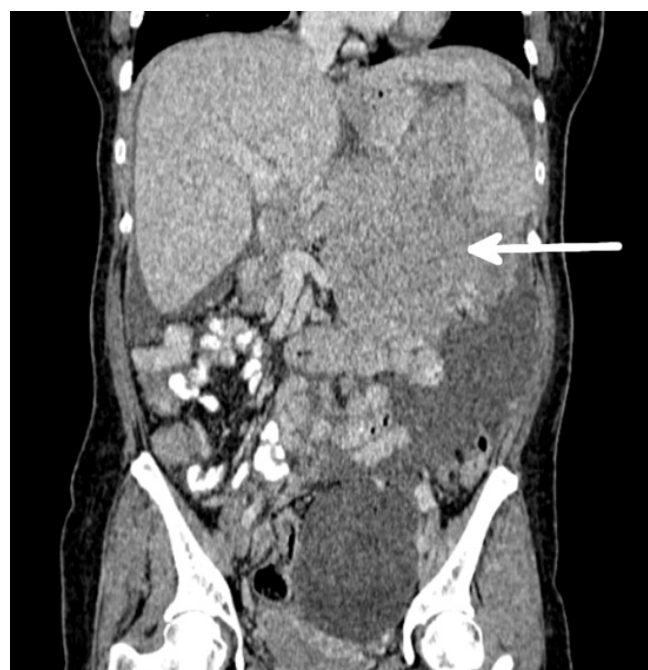

Figure 3: Coronal view of contrast-enhanced computed tomography of pancreatic protocol; the white arrow represents the location of the tumor on the scan.

neoplasm. The tumor was unresectable due to more than 180 degrees encasement of the portal vein. We sent her for a 68Ga-DOTATOC PET scan in West Malaysia which revealed somatostatin-receptor-avid extensive disease in the abdomen with peritoneal, mesenteric, and liver metastasis. After a thorough discussion with our local NEN multidisciplinary team and the patient, we decided for best medical therapy with long-acting somatostatin analogues-lanreotide.

## DISCUSSION

Pancreatic neuroendocrine neoplasms are rare tumors, with an incidence of approximately 0.2/100,000 in the United States and 2.2/100,000 in Asians and only accounts for 1–2% of all pancreatic neoplasms [2, 3]. These tumors commonly occur between the ages of 40 and 60 and have an equal gender distribution [3]. The neoplasm presents in a wide spectrum, ranging from clinically indolent to highly aggressive malignancy. These rare tumors arise from pancreatic islet cells. They present as either functional (hormone secreting) or non-functional neoplasm [4]. Functioning PNENs are associated with hormone secretion related to the pancreas (insulin, glucagon, and somatostatin) and those related to extra-pancreatic tissues (gastrin, vasoactive intestinal peptide, growth hormone releasing factor, and adrenocorticotrophic hormone). The commonest type is that of insulin-producing tumors (insulinoma) with an annual incidence of 1–3/million per year, followed by gastrin-producing tumors (gastrinoma) associated with Zollinger–Ellison syndrome [5]. The majority of PNENs are sporadic, non-functioning, with an annual incidence estimated to be 0.07–0.1/100,000 [6, 7]. A small proportion is associated with genetic diseases—commonly related to multiple endocrine neoplasia type 1, Von Hippel–Lindau syndrome, tuberous sclerosis, and neurofibromatosis [4]. Some may present with obstruction, perforation, and even rarer as bleeding neoplasm, as reported in our first case. To our knowledge, very few case reports are available in the literature on bleeding pancreatic NEN [8–10].

The current WHO classification recognizes three grades of well-differentiated PNENs—pancreatic neuroendocrine tumor (PanNET) of low, intermediate, or high grade. Poorly differentiated high-grade PNENs are all referred to as pancreatic neuroendocrine carcinoma (PanNEC Grade 3) [11, 12].

The critical management step in all neuroendocrine tumors includes diagnosing the disease, identifying associated genetic disorders, hormonal control if functioning tumor, localizing the tumor, deciding on the role of surgical resection if possible, adjuvant therapy and follow-up. First line tools to localize tumors involve high-resolution multiphase CTs or magnetic resonance imaging (MRI) [13, 14]. Positron emission tomography scan with specific radiotracers is a sensitive method for

the detection of the primary tumor and its metastases—most frequently used are somatostatin analogue labeled positron emitters, for example 68Ga-DOTATOC, 68Ga-DOTANOC, and 68Ga-DOTATATE [15, 16]. In the subject of tumor markers, serum CgA and urinary 5-hydroxyindoleacetic acid (5-HIAA) are two widely available markers in current practice. We preferentially use serum CgA as it is released in abnormal amounts by many neoplastic neuroendocrine cells—concentration in the circulation can be measured to provide information for the diagnosis, prognosis, and monitoring of patients with these tumors [17].

Surgery is a curative modality for malignant, sporadic PNEN, as resection of primary tumor improves patient survival [18, 19]. Current guidelines from National Comprehensive Cancer Network (NCCN) and European Neuroendocrine Tumour (ENET) recommend excision of tumors >2 cm [20, 21]. However, for some patients with tumors <1 cm, low-grade, or incidentally discovered, NCCN suggests active observation [21]. For high grade, poorly differentiated PNEN, we offer surgery in conjunction with chemotherapy or radiotherapy. Resecting, both primary and metastatic sites, can be attempted for PNENs with potentially resectable metastatic disease, for example liver metastasis [22]. We advocate medical therapy for unresectable metastatic disease—long-acting somatostatin analogues as the first line and systemic treatment (chemotherapy [oxaliplatin-based regimens], peptide receptor radionuclide therapy [PRRT], tyrosine kinase [sunitinib], inhibitors of mTOR [everolimus]) [23]. Cytoreductive surgery or palliative debulking is an option for clinically significant progressive disease and to alleviate local symptoms. Additionally, we control any functional PNENs with appropriate medical support before any resection. Following resection, surveillance would comprise of serum CgA level monitoring with multiphase CT/MRI or DOTATOC scan as clinically indicated [24, 25].

The patient in our second case underwent a well-orchestrated flow of investigation protocol, adhering to the current guidelines of management for metastatic NEN; however, the first patient did not. The reason for the unconventional approach for our first patient is due to the lack of facilities and specific specializations which are not available in Sarawak, East Malaysia, on the island of Borneo. In an ideal situation, this patient should have undergone a DOTATOC scan, but because of the nature of the case is an upper gastrointestinal bleed, not amenable to endoscopic and endovascular intervention and no DOTATOC scan was available in our center in Sarawak, the decision was made to proceed with emergency surgery. Although this may not be the best approach for patients with pancreatic neoplasm, in a young, healthy patient with imaging suggestive of a NEN, we would suggest an aggressive strategy of surgical intervention as we can successfully treat the extrapancreatic lesions later with adjuvant therapy.



## CONCLUSION

Pancreatic NEN is a heterogeneous group of disorders with varied presentations. Treatment must be planned on a case by case basis, as each patient presents with a clinical problem and diagnostic challenge of its own. Prompt investigation with appropriate intervention is an integral part of the multidisciplinary care of patients with these tumors. In keeping with the purpose of this article, as evidenced by the relevant instances presented, bleeding pancreatic NEN, a rare occurrence, is best managed with surgery, while unresectable metastatic NEN would benefit from appropriate medical therapy.

## REFERENCES

- Oronsky B, Ma PC, Morgensztern D, Carter CA. Nothing but NET: A review of neuroendocrine tumors and carcinomas. *Neoplasia* 2017;19(12):991–1002.
- Halfdanarson TR, Rabe KG, Rubin J, Petersen GM. Pancreatic neuroendocrine tumors (PNETs): Incidence, prognosis and recent trend toward improved survival. *Ann Oncol* 2008;19(10):1727–33.
- Lim CH, Lee IS, Jun BY, et al. Incidence and clinical characteristics of gastroenteropancreatic neuroendocrine tumor in Korea: A single-center experience. *Korean J Intern Med* 2017;32(3):452–8.
- Kasajima A, Yazdani S, Sasano H. Pathology diagnosis of pancreatic neuroendocrine tumors. *J Hepatobiliary Pancreat Sci* 2015;22(8):586–93.
- de Herder WW, Niederle B, Scoazec JY, et al. Well-differentiated pancreatic tumor/carcinoma: Insulinoma. *Neuroendocrinology* 2006;84(3):183–8.
- Watson RG, Johnston CF, O'Hare MM, et al. The frequency of gastrointestinal endocrine tumours in a well-defined population – Northern Ireland 1970–1985. *Q J Med* 1989;72(267):647–57.
- Halfdanarson TR, Rubin J, Farnell MB, Grant CS, Petersen GM. Pancreatic endocrine neoplasms: Epidemiology and prognosis of pancreatic endocrine tumors. *Endocr Relat Cancer* 2008;15(2):409–27.
- Brewer Gutierrez O, Moran R, Bukhari M, Chen YI, Khashab MA. EUS-guided arterial embolization with cyanoacrylate glue of a pancreatic neuroendocrine tumor infiltrating the gastric wall causing upper GI bleeding. *VideoGIE* 2017;2(5):100–1.
- Schütte K, Bornschein J, Kuester D, Wieners G, Malfertheiner P. Fulminant duodenal bleeding as first manifestation of a neuroendocrine carcinoma of the pancreatic head. [Artical in German]. *Med Klin (Munich)* 2010;105(4):291–5.
- Daveson J, Masson J, Cameron D, Jennings M. A case of an isolated gastric variceal bleed secondary to a pancreatic neuroendocrine tumour. *Eur J Gastroenterol Hepatol* 2007;19(12):1144–8.
- Li X, Gou S, Liu Z, Ye Z, Wang C. Assessment of the American joint commission on cancer 8th edition staging system for patients with pancreatic neuroendocrine tumors: A surveillance, epidemiology, and end results analysis. *Cancer Med* 2018;7(3):626–34.
- Morin E, Cheng S, Mete O, et al. Hormone profiling, WHO 2010 grading, and AJCC/UICC staging in pancreatic neuroendocrine tumor behavior. *Cancer Med* 2013;2(5):701–11.
- Moulopoulos A, DuBrow R, David C, Dimopoulos MA. Primary renal carcinoid: Computed tomography, ultrasound, and angiographic findings. *J Comput Assist Tomogr* 1991;15(2):323–5.
- Thompson GB, van Heerden JA, Martin JK Jr, Schutt AJ, Ilstrup DM, Carney JA. Carcinoid tumors of the gastrointestinal tract: Presentation, management, and prognosis. *Surgery* 1985;98(6):1054–63.
- de Herder WW, Lamberts SW. Somatostatin and somatostatin analogues: Diagnostic and therapeutic uses. *Curr Opin Oncol* 2002;14(1):53–7.
- Kartalis N, Mucelli RM, Sundin A. Recent developments in imaging of pancreatic neuroendocrine tumors. *Ann Gastroenterol* 2015;28(2):193–202.
- Yang X, Yang Y, Li Z, et al. Diagnostic value of circulating chromogranin a for neuroendocrine tumors: A systematic review and meta-analysis. *PLoS One* 2015;10(4):e0124884.
- Hill JS, McPhee JT, McDade TP, et al. Pancreatic neuroendocrine tumors: The impact of surgical resection on survival. *Cancer* 2009;115(4):741–51.
- Cheslyn-Curtis S, Sitaram V, Williamson RC. Management of non-functioning neuroendocrine tumours of the pancreas. *Br J Surg* 1993;80(5):625–7.
- Falconi M, Bartsch DK, Eriksson B, et al. ENETS Consensus Guidelines for the management of patients with digestive neuroendocrine neoplasms of the digestive system: Well-differentiated pancreatic non-functioning tumors. *Neuroendocrinology* 2012;95(2):120–34.
- Shah MH, Goldner WS, Halfdanarson TR, et al. NCCN guidelines insights: Neuroendocrine and adrenal tumors, version 2.2018. *J Natl Compr Canc Netw* 2018;16(6):693–702.
- Kulke MH, Anthony LB, Bushnell DL, et al. NANETS treatment guidelines: Well-differentiated neuroendocrine tumors of the stomach and pancreas. *Pancreas* 2010;39(6):735–52.
- Plöckinger U1, Rindi G, Arnold R, et al. Guidelines for the diagnosis and treatment of neuroendocrine gastrointestinal tumours. A consensus statement on behalf of the European Neuroendocrine Tumour Society (ENETS). *Neuroendocrinology* 2004;80(6):394–424.
- Di Giacinto P, Rota F, Rizza L, et al. Chromogranin A: From laboratory to clinical aspects of patients with neuroendocrine tumors. *Int J Endocrinol* 2018;2018:8126087.
- Strosberg JR, Halfdanarson TR, Bellizzi AM, et al. The North American neuroendocrine tumor society consensus guidelines for surveillance and medical management of midgut neuroendocrine tumors. *Pancreas* 2017;46(6):707–14.

\*\*\*\*\*

## Author Contributions

Muthu Viknesh – Conception of the work, Design of the work, Acquisition of data, Analysis of data, Interpretation

of data, Drafting the work, Revising the work critically for important intellectual content, Final approval of the version to be published, Agree to be accountable for all aspects of the work in ensuring that questions related to the accuracy or integrity of any part of the work are appropriately investigated and resolved

Faqihuddin Bin Hisham – Conception of the work, Design of the work, Acquisition of data, Analysis of data, Interpretation of data, Drafting the work, Revising the work critically for important intellectual content, Final approval of the version to be published, Agree to be accountable for all aspects of the work in ensuring that questions related to the accuracy or integrity of any part of the work are appropriately investigated and resolved

Padmaan Sankaran – Conception of the work, Design of the work, Acquisition of data, Analysis of data, Interpretation of data, Drafting the work, Revising the work critically for important intellectual content, Final approval of the version to be published, Agree to be accountable for all aspects of the work in ensuring that questions related to the accuracy or integrity of any part of the work are appropriately investigated and resolved

Soon Kong Choon – Conception of the work, Design of the work, Acquisition of data, Analysis of data, Interpretation of data, Drafting the work, Revising the work critically for important intellectual content, Final approval of the version to be published, Agree to be accountable for all aspects of the work in ensuring that questions related to the accuracy or integrity of any part of the work are appropriately investigated and resolved

Nik Azim Bin Nik Abdullah – Conception of the work, Design of the work, Acquisition of data, Analysis of data,

Interpretation of data, Drafting the work, Revising the work critically for important intellectual content, Final approval of the version to be published, Agree to be accountable for all aspects of the work in ensuring that questions related to the accuracy or integrity of any part of the work are appropriately investigated and resolved

### **Guarantor of Submission**

The corresponding author is the guarantor of submission.

### **Source of Support**

None.

### **Consent Statement**

Written informed consent was obtained from the patient for publication of this article.

### **Conflict of Interest**

Authors declare no conflict of interest.

### **Data Availability**

All relevant data are within the paper and its Supporting Information files.

### **Copyright**

© 2019 Muthu Viknesh et al. This article is distributed under the terms of Creative Commons Attribution License which permits unrestricted use, distribution and reproduction in any medium provided the original author(s) and original publisher are properly credited. Please see the copyright policy on the journal website for more information.

Access full text article on  
other devices



Access PDF of article on  
other devices







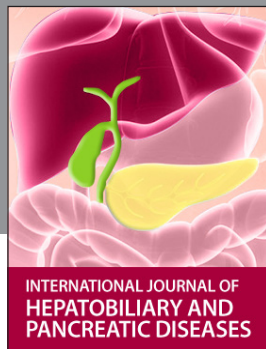INTERNATIONAL JOURNAL OF CASE REPORTS AND IMAGES



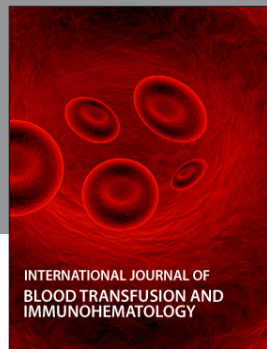VIDEO JOURNAL OF CLINICAL RESEARCH



VIDEO JOURNAL OF BIOMEDICAL SCIENCE




INTERNATIONAL JOURNAL OF HEPATOBILIARY AND PANCREATIC DISEASES



INTERNATIONAL JOURNAL OF BLOOD TRANSFUSION AND IMMUNOHEMATOLOGY



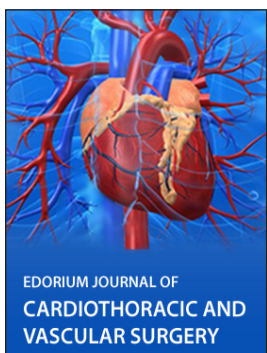EDORIUM JOURNAL OF OPHTHALMOLOGY



**Submit your manuscripts at**  
[www.edoriumjournals.com](http://www.edoriumjournals.com)



EDORIUM JOURNAL OF MEDICINE



EDORIUM JOURNAL OF CARDIOTHORACIC AND VASCULAR SURGERY



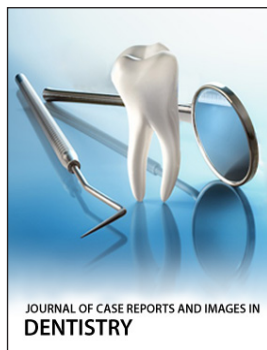
JOURNAL OF CASE REPORTS AND IMAGES IN ORTHOPEDICS AND RHEUMATOLOGY



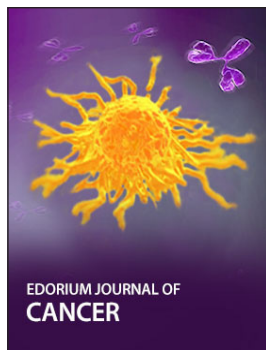
EDORIUM JOURNAL OF PSYCHOLOGY




EDORIUM JOURNAL OF CELL BIOLOGY



JOURNAL OF CASE REPORTS AND IMAGES IN DENTISTRY



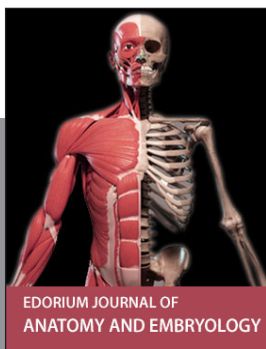EDORIUM JOURNAL OF CANCER



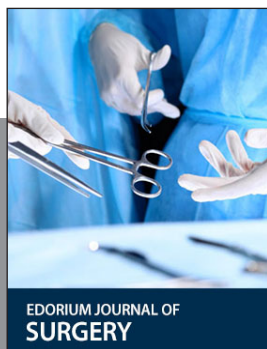EDORIUM JOURNAL OF PSYCHIATRY



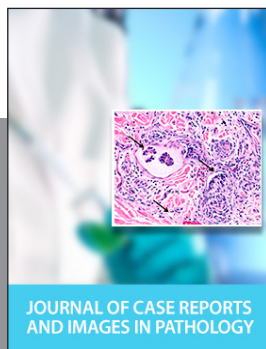JOURNAL OF CASE REPORTS AND IMAGES IN INFECTIOUS DISEASES



EDORIUM JOURNAL OF ANATOMY AND EMBRYOLOGY



EDORIUM JOURNAL OF SURGERY



JOURNAL OF CASE REPORTS AND IMAGES IN PATHOLOGY



EDORIUM JOURNAL OF ANESTHESIA